



5th COMBO Endocrinology International Course

29th September-1st October 2017

ATHENS, GREECE

*Subclinical Endocrinopathies
& Diabetes : To treat or not to treat?*

Subclinical Pheochromocytoma: The unpredictable silence

CASE REPORT

Massimo Mannelli

Dept. of Experimental and Clinical Biomedical Sciences

University of Florence

massimo.mannelli@unifi.it





5th COMBO Endocrinology International Course

29th September-1st October 2017

ATHENS, GREECE

*Subclinical Endocrinopathies
& Diabetes : To treat or not to treat?*

LEARNING OBJECTIVES

Definition of Pheochromocytoma/Paraganglioma (PPGL)

Clinics of PPGL

Diagnosis of PPGL (sPGL and HNPGL)

Genetics of PPGL

Treatment of PPGL



CASE REPORT (November 2010)

Patient: caucasian 56 yrs old man

Incidental right adrenal mass found at sonography for abdominal pain

Question: What next?

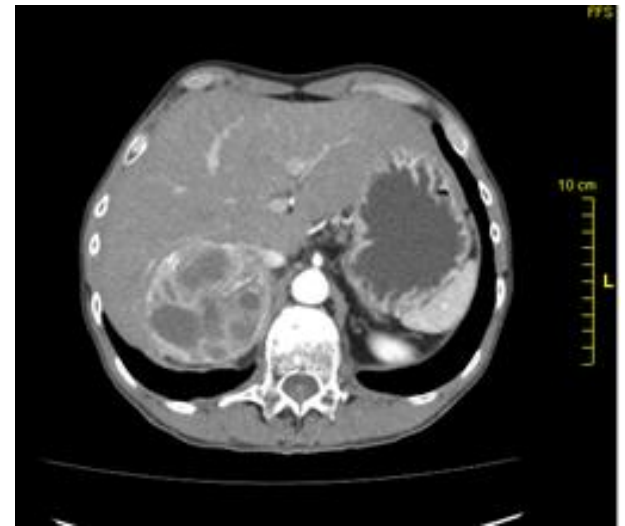
CT

RMI

123-I-MIBG

^{68}Ga -DOTATOC-PET

Other



Referred to the Surgical Dept. of a Northern Italy University Hospital

Question: correct? What next?

CASE REPORT

Family history: referred negative

**Personal history: Rheumatic cardiomyopathy at 15 yrs
Aortic+mitral valve replacement 7 yrs before
No Symptoms reported
Treatment: ASA 100 mg**

**Clinical examination: 173 cm tall; 66,5 Kg; BMI 22,2
supine BP: 143/85 mmHg; HR 69 b/min
upright BP: 138/75 mmHg; HR 75 b/min**

Question: what next?

